

## Neuroscience and Psychiatry

## How COVID-19 Affects the Brain

Maura Boldrini, MD, PhD; Peter D. Canoll, MD, PhD; Robyn S. Klein, MD, PhD

**COVID-19** has resulted in more than 120 million cases and 2.6 million deaths to date. Respiratory and gastrointestinal symptoms are accompanied by short- and long-term neuropsychiatric symptoms (NPs) and long-term brain sequelae.

Some patients present with anosmia, cognitive and attention deficits (ie, brain fog), new-onset anxiety, depression, psychosis, seizures, and even suicidal behavior.<sup>1,2</sup> These present before, during, and after respiratory symptoms and are unrelated to respiratory insufficiency,<sup>1</sup> suggesting independent brain damage. Follow-ups conducted in Germany and the United Kingdom found post-COVID-19 NPs in 20% to 70% of patients, even in young adults, and lasting months after respiratory symptoms resolved,<sup>1</sup> suggesting brain involvement persists.

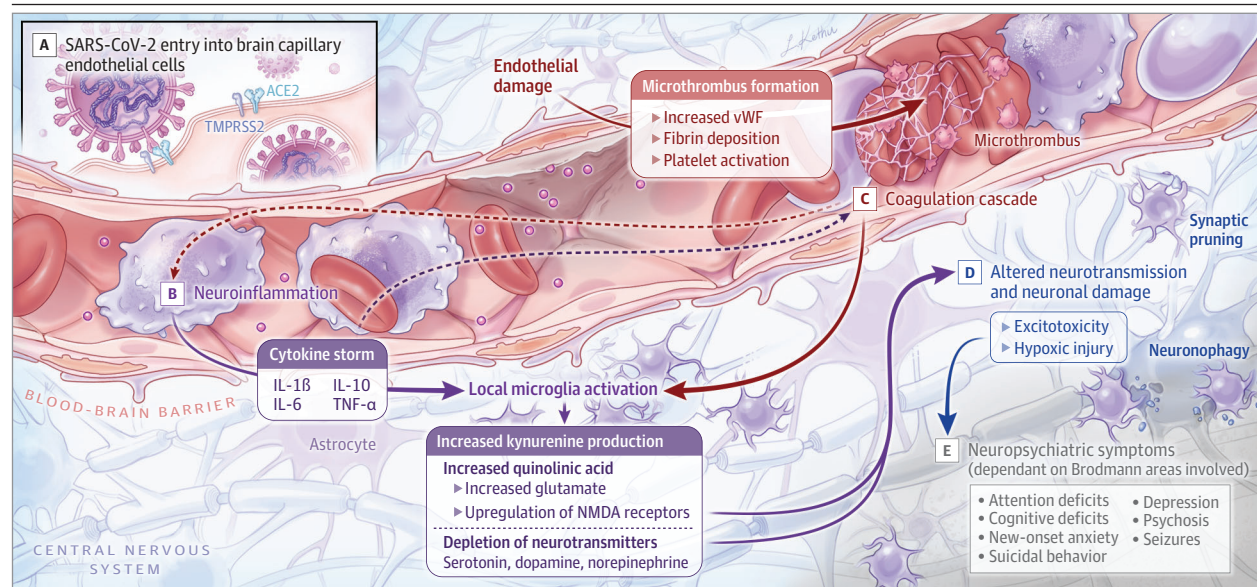
Entering through angiotensin-converting enzyme 2 receptors,<sup>2</sup> SARS-CoV-2 can damage endothelial cells leading to inflammation, thrombi, and brain damage. Moreover, systemic inflammation leads to decreased monoamines and trophic factors and activation of microglia, resulting in increased glutamate and *N*-methyl-D-aspartate (NMDA)<sup>3</sup> and excitotoxicity (Figure). These insults induce new-onset or re-exacerbation of preexisting NPs.

## Does the Virus Invade the Brain?

SARS-CoV-2 is known to penetrate the olfactory mucosa, causing loss of smell, and may enter the brain, migrating from the cribriform plate

along the olfactory tract<sup>2</sup> or through vagal or trigeminal pathways; however, definitive evidence for this is lacking. SARS-CoV-2 could pass the blood-brain barrier (BBB) because inflammatory cytokines induce BBB instability or via monocytes.<sup>4</sup> It could reach brain tissue via circumventricular organs (CVOs), midline structures around the third and fourth ventricles, that monitor blood and cerebral spinal fluid content via fenestrated capillaries lacking the junctional proteins expressed in the BBB. Viral RNA was detected by reverse transcription-quantitative real-time polymerase chain reaction but not by in situ hybridization in medulla and cerebellum,<sup>2</sup> located next to the area postrema, a CVO that controls emetic responses to toxins. SARS-CoV-2 protein has been found in brain vascular endothelium but not in neurons or glia.<sup>2</sup> Thus, detected viral RNA may represent contamination by vasculature in leptomeninges and Virchow-Robin spaces. Histopathologic analysis of whole human brain showed microglial nodules and phagocytosis of neurons (neuronophagia) in brain stem and less frequently in cortex and limbic structures, associated with sparse lymphocytic infiltration, and no correlations between histopathologic findings and levels of viral messenger RNA in the same brain.<sup>5</sup> While ageusia, nausea, and vomiting may be related to CVO and brain stem viral invasion, other short-term and long-lasting NPs are more likely due to neuroinflammation and hypoxic injury. Brain stem involvement may explain persistent autonomic abnormalities and anxiety.

**Figure. Brain Vascular Injury, Neurotransmitter System Dysfunction, Thrombotic Events, Neuronal Damage, and Neuropsychiatric Symptoms**



A, SARS-CoV-2 invades endothelial cells via transmembrane angiotensin-converting enzyme 2 (ACE2) receptor, enabled by transmembrane protease, serine 2 (TMPRSS2). B, Cytokine elevation and microglia activation result in increased kynurenine, quinolinic acid, and glutamate, and neurotransmitter depletion. C, Coagulation cascade and elevation of von Willebrand factor (vWF)

lead to thrombotic events. D, Altered neurotransmission, excitotoxicity by increased glutamate, and hypoxic injury contribute to neuronal dysfunction and loss. E, Neuropsychiatric symptoms differ depending on the Brodmann area involved. IL indicates interleukin; NMDA, *N*-methyl-D-aspartate; TNF, tumor necrosis factor.

### Cytokines and Microglia Activation Lead to Neurotoxicity

Patients with severe COVID-19 infection have been reported to experience a severe cytokine storm, with increased serum levels of pro-inflammatory cytokines including interleukin (IL) 1, IL-6, IL-10, and tumor necrosis factor (TNF)- $\alpha$ . TNF- $\alpha$  can directly cross the BBB by transport (increased BBB permeability due to cytokine-induced damage)<sup>4</sup> or CVOs. Once across the BBB, cytokines activate microglia and astrocytes.<sup>6</sup> In addition to phagocytosing damaged cells, activated microglia secrete inflammatory mediators, including glutamate, quinolinic acid, ILs, complement proteins, and TNF- $\alpha$ .<sup>7</sup> Increased quinolinic acid results in higher glutamate and upregulation of NMDA receptors, possibly inducing altered learning, memory, neuroplasticity, hallucinations, and nightmares. Excitotoxicity and neuronal loss result in region- and neurotransmitter-specific NPs.

### Inflammation and NPs

Increased inflammation activates the enzyme indoleamine dioxygenase, which metabolizes tryptophan to kynurenine rather than serotonin.<sup>3</sup> Reduced neurotransmitter release was demonstrated in patients treated with interferon alpha who exhibited increased positron emission tomography fluorodopa <sup>18</sup>F uptake and decreased turnover in caudate and putamen, which correlated with depression and fatigue severity. Similarly, interferon- or IL-based immunotherapy can induce depression. Inflammation leads to blunted monoamine neurotransmission, anhedonia, negative cognitive, psychomotor and neurovegetative symptoms, depression, and suicidal behavior, which poorly respond to conventional antidepressants.<sup>3</sup> In individuals who attempt suicide and have major depressive disorder, studies found elevated plasma kynurenine, high IL-1 and IL-6 levels in blood, cerebral spinal fluid, and brain, and increased serum C-reactive protein correlating with brain glutamate levels. TNF- $\alpha$  and IL-6 levels may predict negative and depressive symptoms in people at risk of psychosis, and higher IL-6 correlates with smaller hippocampus volume. Elevated IL-1 $\beta$  signaling decreases hippocampal neurogenesis and

increases apoptosis in mammals. Suicide decedents with major depressive disorder have increased proinflammatory and decreased neurogenesis markers in postmortem hippocampus,<sup>8</sup> together with smaller dentate gyrus, fewer granule neurons, and neural progenitor cells.<sup>9</sup> Therefore, neuroinflammation may contribute to the pathogenesis of NPs reducing neurotransmitters and neurotrophins and increasing excitotoxicity.<sup>3</sup>

### Interplay of Inflammation and Coagulation

Virus entrance into endothelial cells of brain vasculature activates neutrophils, macrophages, thrombin production, and complement pathways, promoting microthrombi deposition.<sup>2</sup> COVID-19 brain damage shows macro- and micro-hypoxic/ischemic injury and infarcts at autopsy.<sup>5</sup> Moreover, the complement cascade mediates synaptic pruning by microglia following viral infections.<sup>7</sup> Therefore, NPs of COVID-19 could result from microstrokes and neuronal damage, and symptoms consequently differ depending on the brain region involved. Mechanisms of COVID-19 brain damage may resemble those involved in traumatic brain injury, where a combination of proinflammatory status and microvascular injury resulting in neuronal loss have been implicated in the pathogenesis of suicidal behavior.<sup>10</sup> Conversely, a successful clinical outcome would result from an initial immune response involving toll receptors and blunted nonpriming or low-priming delayed inflammation.

Understanding cellular and molecular aspects of COVID-19 brain damage could direct interventions to reduce long-term NPs. Interventions may involve antagonists of cytokines (etanercept, infliximab), NMDA receptor (ketamine), TNF- $\alpha$  and anti-inflammatory pathways (aspirin, celecoxib), and kynurenine pathway modulators (minocycline).<sup>3</sup> Mitigating long-term post-COVID-19 cognitive, emotional, and behavioral sequelae would decrease disease burden. COVID-19 neuropathology may serve as a model for deciphering neurodegenerative processes related to neuroinflammation in other brain diseases and developing new treatment strategies.

#### ARTICLE INFORMATION

**Author Affiliations:** Division of Molecular Imaging and Neuropathology, New York State Psychiatric Institute, New York (Boldrini); Department of Psychiatry, Columbia University, New York, New York (Boldrini); Department of Pathology and Cell Biology, Columbia University, New York, New York (Canoll); Department of Medicine, Washington University School of Medicine in St Louis, St Louis, Missouri (Klein); Department of Neuroscience, Washington University School of Medicine in St Louis, St Louis, Missouri (Klein); Department of Pathology & Immunology, Washington University School of Medicine in St Louis, St Louis, Missouri (Klein).

**Corresponding Author:** Maura Boldrini, MD, PhD, Department of Psychiatry, New York State Psychiatric Institute, Columbia University Irving Medical Center, 1051 Riverside Dr, Unit 42, New York, NY 10032 (mb928@cumc.columbia.edu).

**Published Online:** March 26, 2021. doi:10.1001/jamapsychiatry.2021.0500

**Conflict of Interest Disclosures:** Dr Boldrini is supported by the National Institutes of Health, the American Foundation for Suicide Prevention, Dr Brigitte Rok Foundation, and the Morris Stroud III

Center for Study of Quality of Life in Health and Aging at Columbia University. Drs Canoll and Klein are supported by the National Institutes of Health.

**Additional Contributions:** We thank Helen Blair Simpson, MD, PhD (New York State Psychiatric Institute and Columbia University), for reviewing a draft of this work. Dr Simpson was not compensated.

#### REFERENCES

1. Woo MS, Malsy J, Pöttgen J, et al. Frequent neurocognitive deficits after recovery from mild COVID-19. *Brain Commun*. 2020;2(2):fcaa205. doi:10.1093/braincomms/fcaa205
2. Meinhardt J, Radke J, Dittmayer C, et al. Olfactory transmucosal SARS-CoV-2 invasion as a port of central nervous system entry in individuals with COVID-19. *Nat Neurosci*. 2021;24(2):168-175.
3. Roman M, Irwin MR. Novel neuroimmunologic therapeutics in depression. *Brain Behav Immun*. 2020;83:7-21. doi:10.1016/j.bbi.2019.09.016
4. Daniels BP, Holman DW, Cruz-Orengo L, Jujavarapu H, Durrant DM, Klein RS. Viral pathogen-associated molecular patterns regulate blood-brain barrier integrity via competing innate cytokine signals. *mBio*. 2014;5(5):e01476-e14. doi:10.1128/mBio.01476-14
5. Al-Dalahmah O, Thakur KT, Nordvig AS, et al. Neuronophagia and microglial nodules in a SARS-CoV-2 patient with cerebellar hemorrhage. *Acta Neuropathol Commun*. 2020;8(1):147. doi:10.1186/s40478-020-01024-2
6. Liddel SA, Guttenplan KA, Clarke LE, et al. Neurotoxic reactive astrocytes are induced by activated microglia. *Nature*. 2017;541(7638):481-487. doi:10.1038/nature21029
7. Vasek MJ, Garber C, Dorsey D, et al. A complement-microglial axis drives synapse loss during virus-induced memory impairment. *Nature*. 2016;534(7608):538-543. doi:10.1038/nature18283
8. Mahajan GJ, Vallender EJ, Garrett MR, et al. Altered neuro-inflammatory gene expression in hippocampus in major depressive disorder. *Prog Neuropsychopharmacol Biol Psychiatry*. 2018;82:177-186. doi:10.1016/j.pnpbp.2017.11.017
9. Boldrini M, Galfalvy H, Dwork AJ, et al. Resilience is associated with larger dentate gyrus, while suicide decedents with major depressive disorder have fewer granule neurons. *Biol Psychiatry*. 2019;85(10):850-862. doi:10.1016/j.biopsych.2018.12.022
10. Wadhawan A, Stiller JW, Potocki E, et al. Traumatic brain injury and suicidal behavior. *J Alzheimers Dis*. 2019;68(4):1339-1370. doi:10.3233/JAD-181055